A Case of Acrokeratosis Elastofiberoid Disease

Lifeng Zhou[1] and Rong Lu[2*]

[1]Department of Dermatology, the 942nd Hospital of the PLA Joint Logistic Support Force, Yinchuan City, Ningxia Province, 750004, China

[2]Department of Pathology, the 942nd Hospital of the PLA Joint Logistic Support Force, Yinchuan City, Ningxia Province, 750004, China

Email: 2759216530@qq.com

*corresponding author

Statement:Correspondent author - Rong Lu's contribution in this paper is equal to that of the first author.

Keywords: Elastofiberoid Disease; Acrokeratosis; Diagnostic Method; Avinoic Acid; Adverse Reactions

Abstract: The objective is to investigate the diagnostic method and effect of acrokeratosis elastofiberoid disease. Method: One patient who was diagnosed with acrokeratinoid elastofibroidosis in our hospital in March 2018 was selected as the object. After admitted to our hospital, further examinations were conducted for the patient to understand the patients' past medical history so as to finally complete physical examination, and the examination in dermatology department was accomplished. Besides, histopathological examination of the skin was conducted for the patient and corresponding treatments were formulated according to the results of the examination. Results: Integration of the clinical manifestations and histopathological examination. Diagnosis:It was diagnosed with crokeratosis elastofiberoid. Treatment: The patient was advised to receive oral treatment with abretaic acid, but the patient failed to not receive treatment due to concerns on the side effect of the drug. Follow-up was not implemented. Conclusions: The acrokeratoid elastofibroidosis is a rarely seen disease and more examinations in skin histomathological examination will be conducive to make a definite diagnosis of the disease. Good results can be obtained by the treatment for patients with Averin acid. However, the incidence of adverse drug reactions is high, so vital signs monitoring for patients should be strengthened to promote the recovery of patients.

Acrokeratinoelastic fibroidosis is a rare skin disease of keratinoelastic tissue degeneration in the hands and feet, also known as collagenous plaques of foot [1, 2].Previous studies have shown [2] that acrokeratinoid elastofibroidosis is most likely to occur in young or middle-aged people, and the patients were mostly around 20 years old, which has nothing to do with gender or race.At present, clinically, the pathogenesis of acrokeratinoid elastofibroidosis has not been clarified, Lesions mainly occur in the palmoplantar, the skin at the junction of dorsal and volar hand and foot, the line between thumb and index finger, also occur in the dorsal and nail bed of hand and foot joints in some patients, or in front of the shin and tibia, presenting a symmetrical distribution [4].Studies by domestic scholars have shown that[5]: Acrokeratinoid elastofiberosis is mostly scattered or densely distributed, and when it is densely distributed, presenting "paving stone" distribution,and thus affecting the functions of limbs and joints of patients.Therefore, it is of great significance to strengthen the diagnosis and treatment of patients with acrokeratosis elastofiberoid disease to improve the prognosis of patients.In this study, patients with acrokeratosis elastofibroidosis were selected as the objects to explore the diagnostic methods and effects of acrokeratosis elastofibroidosis, as reported below.

1. Materials and Methods

1.1 Clinical Data

The patient was a male at the age of 21 and he came to our hospital in March 2018 due to bilateral skin rash for more than 5 months. Five months prior to the our hospital, the patient showed symptom of keratinized papules on the lateral edges of both hands, keratinized plaques on the extension of the phalangeal joints of both thumbs, and keratinized plaques on the extension of the phalangeal joints of the middle phalangeal joints of both little fingers, which were not itchy without any treatment. However, increasing rashes appeared gradually. The patient was in good health before, without the recent and long-term history of medication and the history of endocrine and metabolic diseases as well as the history of chronic diseases. Due to the nature of work, his hands were exposed to the sun for a long time and his hands were stimulated by friction frequently. There is no history of similar disease in the family. Physical examination: Systematic examination showed no abnormality. Dermatologist check: hands were shaped by thenar eminence. Polygonal and round keratinic papules were symmetrically distributed at the palmar and dorsal junction of the thumb, the hypothenar of both hands and the palmar and dorsal junction of the little finger. The rash was pale white, translucent, smooth with hard texture, and was non-fused, which was densely arranged in a linear pattern with the appearance like paving stone. The extensives of the phalangeal joints of both thumbs and the extensives of the middle phalangeal joints of both little fingers were distributed with keratogenic plaques, as shown in Figure 1 and Figure 2.

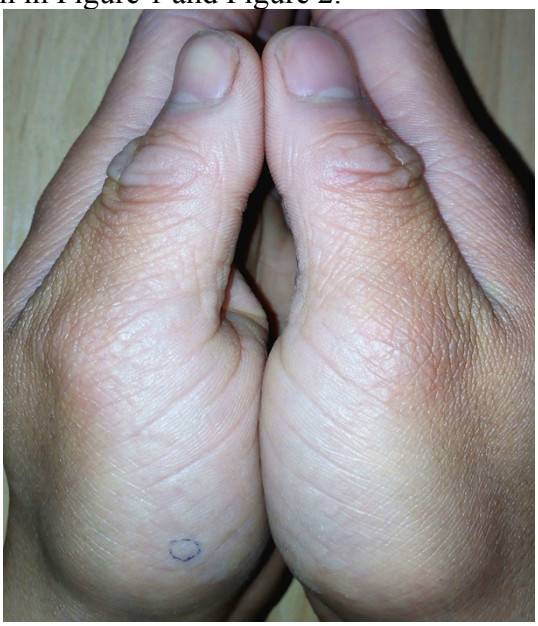

Figure 1. Skin lesions of patients with acrokeratosis elastofiberoid disease

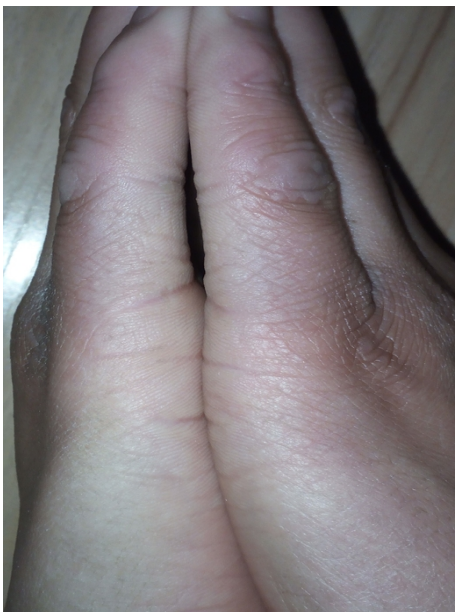

Figure 2. Skin lesions of patients with acrokeratosis elastofiberoid disease

Histopathological examination of the skin lesions showed hyperkeratosis of the epidermis, thickening of the granular layer, hypertrophy of the spinous layer, elongation of the mastoid process, a small amount of inflammatory cell infiltration around the vessels in the superficial dermis, distortion and deformation of collagen fibers, and rupture and reduction of elastic fibers, as shown in Fig. 3, Fig. 4, Fig. 5 and Fig. 6.

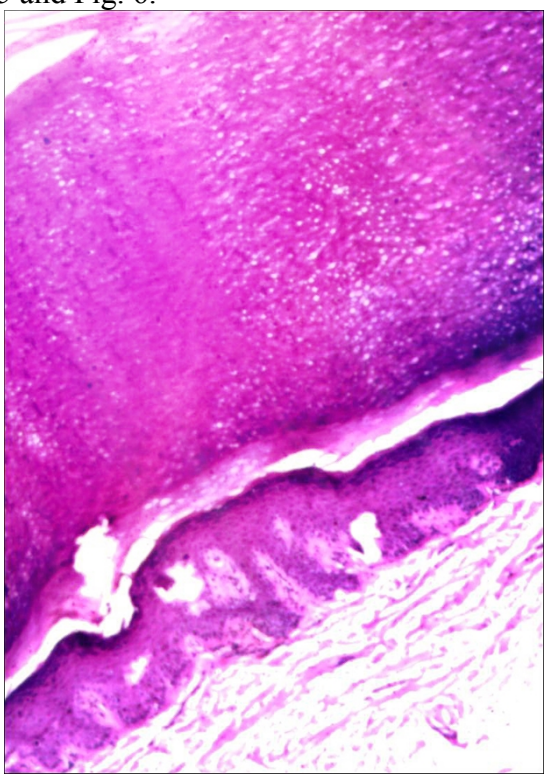

Figure 3. Histopathology of skin lesions in patients with acrokeratosis elastofibroidoid disease (HE staining ×40)

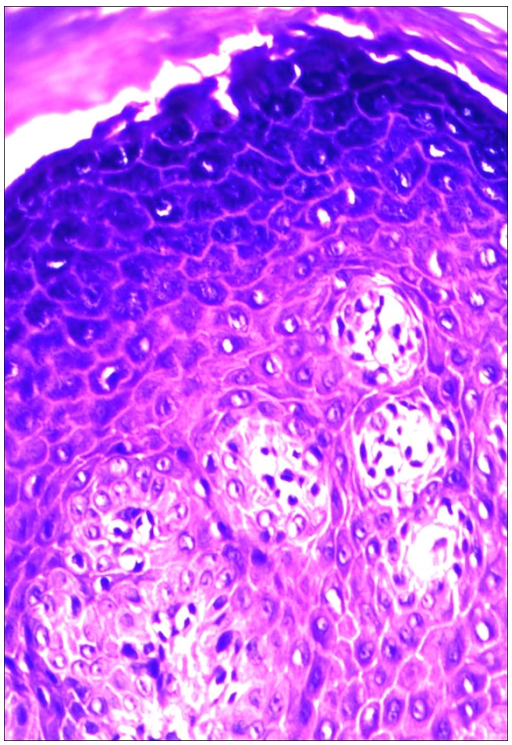

Figure 4. Histopathology of skin lesions in patients with acrokeratosis elastofibroidoid disease (HE staining ×100)

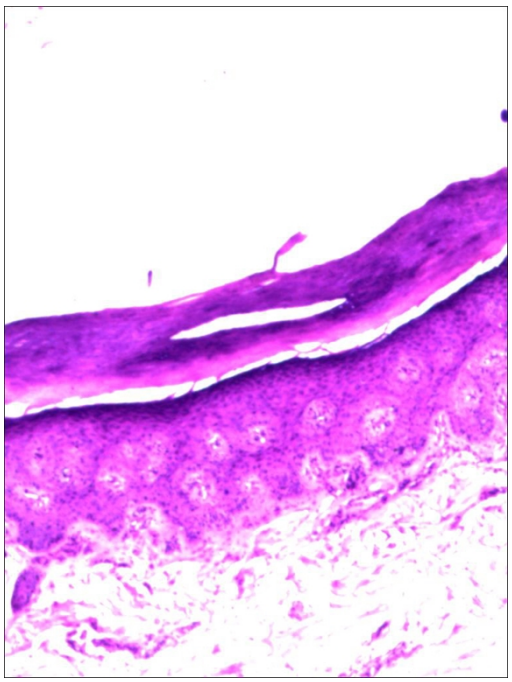

Figure 5. Histopathology of skin lesions in patients with acrokeratosis elastofibroidoid disease (HE staining ×40)

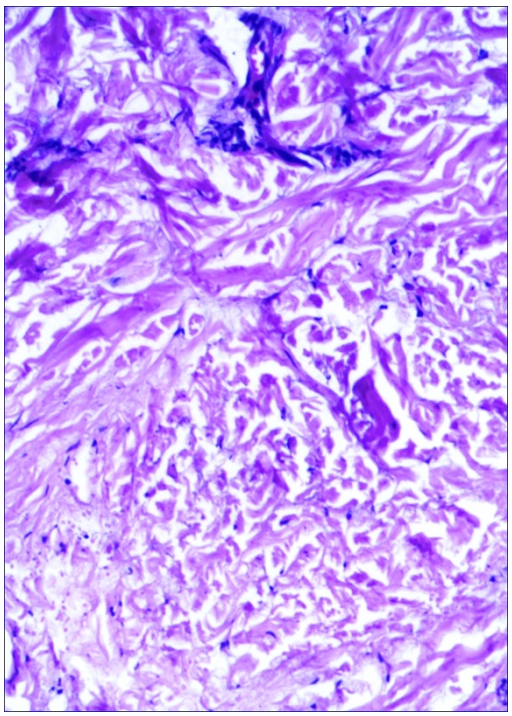

Figure 6. Histopathology of skin lesions in patients with acrokeratosis elastofibroidoid disease (HE staining ×100)

2 Results

Relevant examinations were finished for the patient and we can have a better understanding the medical history and past medical history of the patient, etc. According to the clinical manifestations of the patients and histomathological examination, the diagnosis demonstrated that he was diagnosed with acrokeratinoid elastofiberosis. Treatment: The patient was advised to receive oral administration with abretaic acid. Due to the side effects of drug, the patient did not receive treatment and was not followed-up.

3 Discussion

Acrokeratosis elastofiberoid disease was initially reported by Costa in 1953 as autosomal dominant genetic disease, which can be a familial disease, and the disease is a rare seen in clinical practice. The disease is also known as collagen plaque with acral keratosis elastic fiber tissue degeneration, it is a skin disease occurring in the hands and feet, the cause of the disease is unknown. Sun exposure and trauma are the triggering factors, which can be divided into familial type and adult type: familial type is related to chromosome 2, and adult type is related to light and trauma [6].The main clinical manifestations were linear hyperkeratosis papules on the dorsal and volar boundary of the palm. The skin lesions were translucent, pale yellow or white in round shape and polygonal papules were characterized with hard texture without itching. Histological manifestations were dermal elastic fiber fragmentation. The disease is rarely reported in China.Acrokeratinoid elastofibroidosis is a relatively rare elastic tissue lesion of acrokeratinoid elastofibroidosis. Patients often see the symptoms in the skin of hands and feet after onset, and most of the skin lesions occur near the dorsal side and the connection line between the thumb and the forefinger.Rashes can also occur on the dorsal knuckles and nail beds, and occasionally on the anterior tibial skin of the lower leg.Its clinical features were charaterized with glossy keratinic papules, skin color, translucency with diameter ranged between(2-4) mm, dispersed and irregular distribution, linear distribution, clear boundary, and most patients have no obvious subjective symptoms[7].In this study, 5 months before the admission of the patient, the patient came to the clinic after finding keratinized papules on the lateral edges of both hands, keratinized plaques on the

extensives of the phalangeal joints of both thumbs, and keratinized plaques on the extensives of the phalangeal joints of the middle phalangeal joints of both little fingers, which were not itchy,and not more treatments were performed. Consequently, increasing rashes appeared and the patient came for treatment.

In this study, skin histopathological examination showed epidermal hyperkeratosis, thickening of granular layer, acanthosis, mastoid extension, A few inflammatory cells infiltration around the vessels in the superficial dermis, collagenous distortion, deformation, fracture and reduction of elastic fiber, the clinical manifestations and skin histomathology of the patient were consistent with the diagnostic criteria of acrokeratinoid elastofiberosis. However, the clinical diagnosis of the patient needs to be differentiated from the following diseases: ① Pseudoxanthoma elasticum: it is characterized with extensive elastic fiber degeneration and is prone to occur in neck, axilla and other parts;②Colloid Milium: There are no involved areas between the surface dermis, and colloid degeneration in the tissue;③Focal acrokeratosis: More females were proved to have family relevant family medical history without inelastic fiber fragmentation in pathology.④ Elastofibropathy of marginal keratosis: Histopathological manifestations include thickening of elastic fibers and degeneration of collagen fibers [3].This patient has the following characteristics: ①Young male, the hands were long exposed in sunshine with frequent friction stimulation;② The lesions were distributed in the dorsal and volar junction lines of the skin and the extension of the phalangeal joint;③ The lesions on the dorsal and volar junction lines were papules, while the lesions on the extensor side of the joint were plaques[8].④ The distribution of the rash was symmetrical.It is rarely seen clinically. The incidence may be related to long-term sun exposure and frequent mechanical friction stimulation of hands. Whether there are other reasons is still unclear, and further study is needed [9].In this study, relevant examinations for all the enrolled patients were completed to understand their medical history and past history, etc. According to the clinical manifestations and histomathological examination, the diagnosis was: acrokeratinoid elastofiberosis.Treatment: The patient was advised to take abretaic acid orally. Due to side effects pf drug, the patient did not receive treatment and was not followed-up. Therefore, for patients with acrokeratinoid elastofibroidosis, the relevant examinations should be improved clinically, the physical state should be evaluated, and the pathological examination of patients should be strengthened. For confirmed patients, conservative treatment can be given, and if necessary, averoic acid can be given to promote the recovery of patients for treatment [10].

In conclusion, the incidence of acrokeratoid elastofibroidosis is rarely discovered in clinical practice, and strengthening the skin histomathological examination of patients is conducive to the diagnosis of patients, and the treatment of patients with Averin acid can achieve good results, but the incidence of adverse drug reactions is high, so the vital signs monitoring should be strengthened to promote the recovery of patients.

References

[1] Zhao Bian. Chinese clinical dermatology.The 2nd Edition.Nanjing: Jiangsu Phoenix Science Press, 2017:1231.

[2] Weng Liqiang, Chen Jun, Zhang Chunping, et al.Elastofibroidosis of acrokeratosis .Journal of Clinical Dermatology, 2017, 46 (1): 52-53.

[3] Wang Chunyou, Yang Xichuan, Hao Fei, et al.A case of acrokeratosis elastofiberoid disease.Journal of Applied Dermatology, 2015,8 (5) : 388-389.

[4] Liu Qi, Li Jin, Shen Bo, et al.A clinical study of symmetric acrokeratosis: A report of 9 cases. Progress in Modern Biomedicine, 2018, 18 (08):1556-1559.

[5] Lin Xinyu, Zhao Yan, Fang Fang, Elastofibrous pseudxanthoma complicated with Graves' disease: a case report and literature review.Journal Of Fujian Medical University,2019,53 (01) :65-66.

[6] Zhao Xiaoyan, Cai Liangqi, Zhang Linglin, et al. NF1 gene mutation analysis on neurofibromatosis type Ⅰ sporadic cases.Chinese Journal of Medical Genetics, 2020, 5 (8) : 871-874.

[7] Dong Xiaofeng. Ⅰ neurofibromatosis related to peritoneal malignant tumor and the literature review.Jinagsu Medical Journal, 2019, 45 (12):1291-1293.

[8] Meng Xiaohui, Zhang Hang, Dong HuitingA case of myxoid neurofibroma based type 1 neurofibromatosis.J ChineseJournalofDermatology, 2019,52 (5) :335-336.

[9] Zhang Zhigang, Ye Bin, Yu Yongguo, et al. A case report of type 1 neurofibromatosis complicated with clitoral hypertrophy.Journal of Clinical Pediatrics, 2018, 36 (12):42-44.

[10] Good A J,Snodgrass A L,De Benedetto A, et al. Collagenous and elastotic marginal plaques of the hand: A potential clue to the diagnosis of alkaptonuria. Journal of Cutaneous Pathology, 2018, 46(1):74-79.